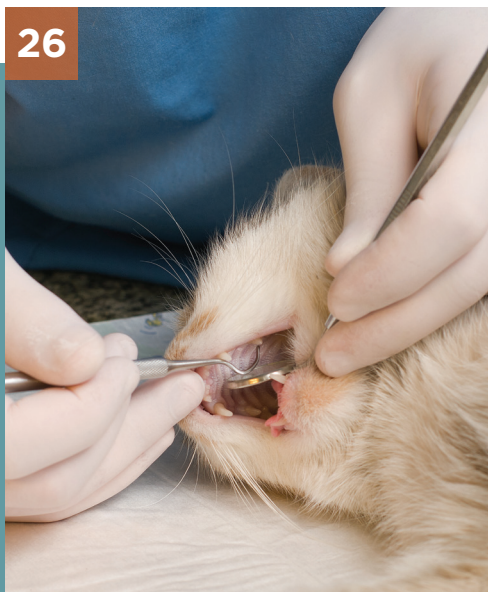




26



RACE-APPROVED CE CREDIT ARTICLE

## Chronic Feline Gingivostomatitis: Proven Therapeutic Approaches & New Treatment Options

*Barden Greenfield, DVM, DAVDC, FAVD*

Chronic gingivostomatitis (CGS) in the cat is a very painful disease, characterized by severe inflammation of the gingiva, buccal mucosa, and caudal oral mucosa. This article reviews clinical signs of CGS, current treatment modalities, and promising treatment options that may be available soon.

40




RACE-APPROVED CE CREDIT ARTICLE

## Treatment Guidelines for Chronic Kidney Disease in Dogs & Cats: International Renal Interest Society Recommendations

*Gregory F. Grauer, DVM, MS, DACVIM*

The International Renal Interest Society (IRIS) was created to advance the scientific understanding of kidney disease in small animals and to help practitioners better diagnose, understand, and treat canine and feline renal disease. This article discusses the latest IRIS guidelines on treatment of chronic kidney disease.



ON OUR COVER

## February is National Pet Dental Health Month

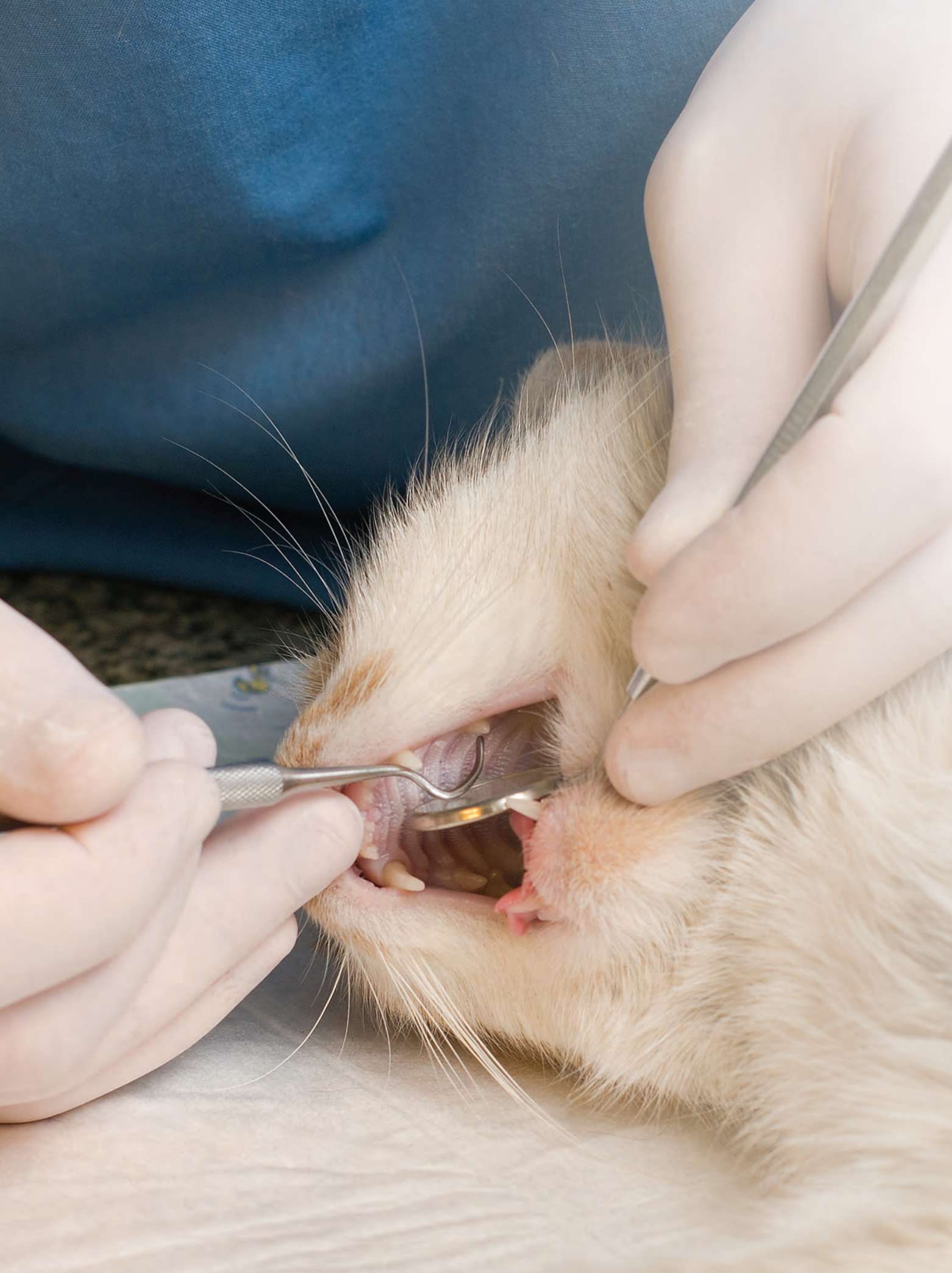Dental health is a key component of overall pet health, and dental problems can cause, or be caused by, other health problems. A pet's teeth and gums should be examined and radiographed at least annually to assess for early signs of disease. The American Veterinary Medical Association (AVMA) reports that 80% of dogs and 70% of cats have some kind of oral disease by the age of 3. Read more at [avma.org](http://avma.org).

Cover photo courtesy of [Shutterstock.com/rawpixel.com](http://Shutterstock.com/rawpixel.com)

- 10 ADVERTISER INDEX
- 14 NAVC PERSPECTIVES
- 16 TODAY'S VETERINARY NEWS









CONTINUING EDUCATION

CHRONIC FELINE GINGIVOSTOMATITIS:

# Proven Therapeutic Approaches & New Treatment Options

**Barden Greenfield, DVM, DAVDC, FAVD**

*Memphis Veterinary Specialists, Cordova, Tennessee*

*Arkansas Veterinary Specialists, Little Rock, Arkansas*

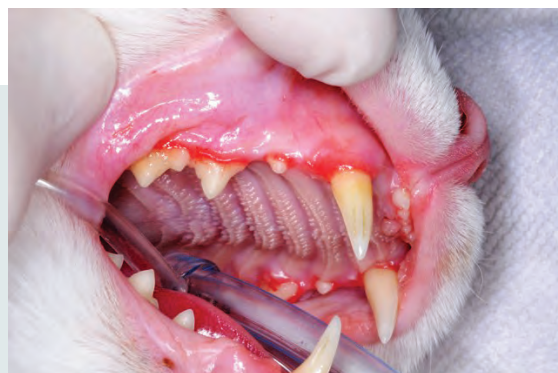Chronic gingivostomatitis (CGS) in the cat is a very painful disease, characterized by severe inflammation of the gingiva, buccal mucosa, and caudal oral mucosa.<sup>1</sup> CGS affects 0.7% to 10% of the general cat population.<sup>2</sup>

This article reviews clinical signs of CGS, current treatment modalities, and promising treatment options that may be available soon.

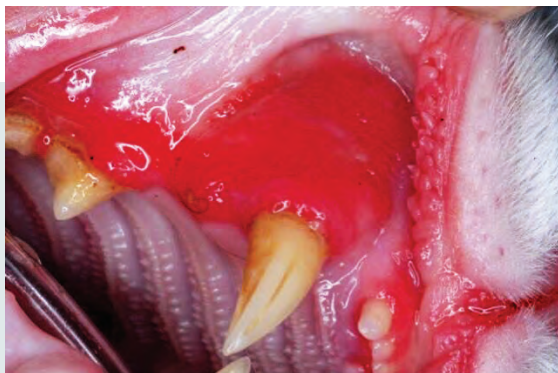
## IDENTIFYING INFLAMMATION

It is important to differentiate gingivitis from stomatitis: *gingivitis* is inflammation of the gingiva (**Figure 1**), while *stomatitis* is inflammation of the mucous lining of any of the structures in the mouth. In clinical use, the term *stomatitis* should be reserved to describe wide-spread oral inflammation (beyond gingivitis and periodontitis) that may also extend into submucosal tissues (**Figure 2**).<sup>3</sup>

The mucogingival (MG) line provides a landmark at which the clinician differentiates disease entities. Routine gingivitis does not extend beyond the gingiva, while stomatitis always extends beyond the MG line.



**FIGURE 1.** Gingivitis; note that inflammation is relegated to the gingival margin only.



**FIGURE 2.** Chronic gingivostomatitis of the right maxilla.

## Etiology of Chronic Gingivostomatitis

This disease process of CGS is a result of an inappropriate immune response to oral antigenic stimulation and, unfortunately, there may be one or more initiating causes that trigger this event.

Dental plaque bacteria, even in very small amounts, have been shown to stimulate the immune system. At one time, it was thought that, in addition to plaque bacteria, this clinical phenomenon might have contributing factors, such as an infectious agent (ie, feline calicivirus [FCV], feline leukemia virus [FeLV], feline herpesvirus, feline immunodeficiency virus [FIV], and *Bartonella henselae*).

Recent studies focused on the shedding of FCV as an active virus in clinical cases of CGS and found no association of viral shedding with FeLV, FIV, herpesvirus, and *Bartonella*.<sup>5,6</sup>

While it is clinically important to know the immunologic status (ie, FeLV or FIV positive/negative) of the patient at the time of the examination, these disease processes may not necessarily be causative agents, but can contribute to the morbidity of the patient in the healing phase of treatment.

- When stomatitis extends into the alveolar and buccal mucosa, it is defined as alveolar or rostral stomatitis.
- When inflammation occurs in the caudal oropharynx lateral to the palatoglossal folds, it is identified as caudal mucositis or stomatitis.<sup>1,3,4</sup>

## DIAGNOSIS

### Clinical Signs

Clinical signs of CGS can be quite variable among cats (**Table 1**), but most experience moderate to severe oral pain and, in severe cases, cats may cry when their mouths are opened.

**TABLE 1** Clinical Signs of Chronic Gingivostomatitis

Weight loss and/or reluctance to eat
Dropping food
Vocalization while eating; then “running away” from food
Hypersalivation
Failure to groom
Oral malodor

## Diagnostic Findings

Oral examination findings include:

- Inflammation of the oral mucosa (**Figure 2**)
- Inflammation of the alveolar and buccal mucosa of premolars and molars (most often symmetrical) and caudal oropharynx (**Figure 3**).

Simultaneous tooth resorption (TR) and/or periodontitis (inflammation at the tooth surface and of surrounding alveolar bone) may occur.<sup>1,4</sup>

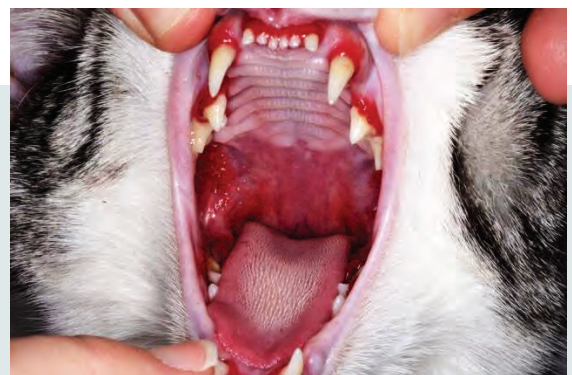In some patients, hyperglobulinemia is present.<sup>2</sup> However, neutrophilia is *not* a hematologic finding in cats with CGS.

## PARTIAL OR FULL MOUTH EXTRACTIONS

Successful treatment of CGS requires the minimization of oral bacteria.<sup>1</sup> The most favorable clinical control for resolution of oral inflammation is via partial or full mouth complete tooth extractions (**Figures 4–6**).

In addition to complete tooth extraction, the marginal bone should receive alveoplasty (smoothing bone and alveolus to remove ridges and spicules). Only American Veterinary Dental College (AVDC) specialists or veterinarians with extensive experience in feline extraction should consider approaching these cases surgically.

Recently, an article was published with the objective of evaluating the long-term response of cats with



**FIGURE 3.** Caudal mucositis associated with chronic gingivostomatitis.

stomatitis to tooth extraction. The data concluded that “extraction of teeth in areas of oral inflammation provided substantial improvement or complete resolution of stomatitis in more than two-thirds of affected cats.”<sup>7</sup> Furthermore, full mouth extractions did not appear to provide additional benefits.<sup>7</sup>

If there is any inflammation of the mucosa of the canine teeth or incisors, those teeth must be removed. The effectiveness of dental extractions has been shown to be: 55% cure, 35% markedly improved, and 10% no improvement.<sup>8,9</sup>

## Efficacy of Periodontal Therapy

Periodic periodontal therapy that includes scaling, polishing, and probing results in minimal success due to the fact that dental plaque bacteria repopulate and initiate the inflammatory cascade soon after therapy. Home care is usually

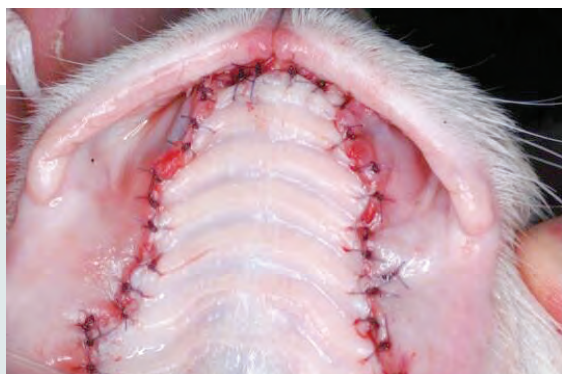unrewarding as cats are resistant to daily or twice-daily tooth brushing and oral rinses.

## Dental Radiography

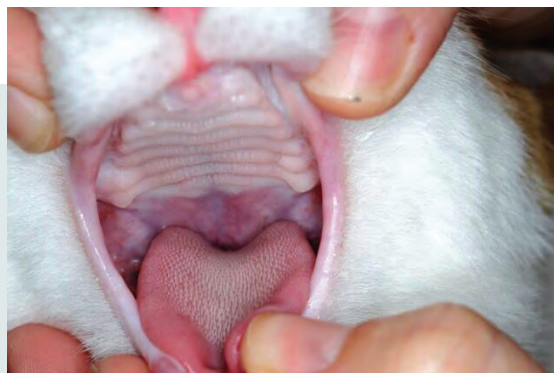
With extractions, emphasis is placed on the absolute need that all root structures must be removed, as any tooth root remnant will not allow for resolution or improvement of clinical signs (**Figure 7**). It is my opinion and that of other AVDC specialists that extractions should only be completed with the aid of dental radiography to confirm complete tooth root extraction.

## Histopathology

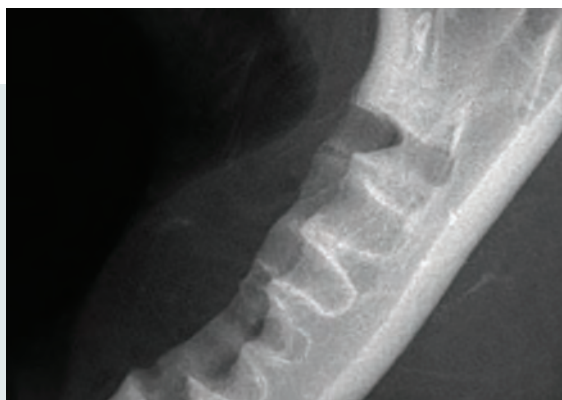Histopathology of inflamed mucosa and gingiva reveal plasma cells with varying numbers of lymphocytes, neutrophils, and macrophages.



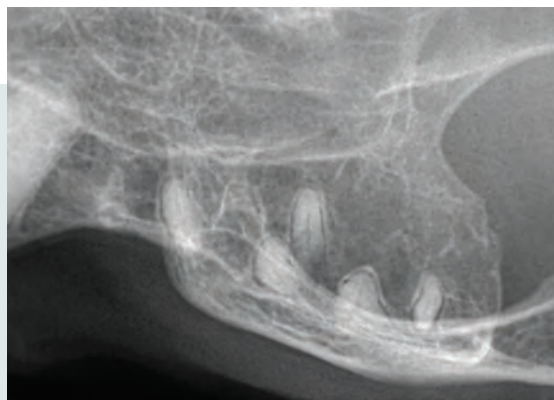**FIGURE 4.** Postoperative image of mandible after full mouth extractions in a 3-year-old cat.



**FIGURE 6.** Clinical resolution of chronic gingivostomatitis in a 3-year-old cat.



**FIGURE 5.** Postoperative radiograph confirming complete tooth extraction in **Figure 4** cat.



**FIGURE 7.** Tooth root remnants in patient with refractory CGS. This cat did not respond favorably to therapy due to incomplete tooth extractions.





## Learn More

Read **A Review of Feline Oral Squamous Cell Carcinoma** in the November/December 2016 issue of *Today's Veterinary Practice*, available at [tvpjournal.com](http://tvpjournal.com).

Mast cells may be seen in higher numbers, but they can also be seen in cases of periodontitis and tooth resorption.<sup>4</sup> Rarely is histopathology warranted, unless unilateral lesions are seen. Histopathologic differentiation between CGS and neoplasia is needed for those particular cases.

## Patient Preparation

For those cats that eat hard food as their sole diet, a transition to canned food is needed prior to surgery. This canned diet should continue for all cats at least 2 to 3 weeks postoperatively. An appetite stimulant (eg, mirtazapine, 3.75 mg/cat PO Q 72 H) may help cats adjust to the new texture and diet and can be continued through the posttreatment phase.

## Pain Management

Pain management is recommended, not only in the pre- and postoperative phases, but also the intraoperative phase (**Table 2**).

- Buprenorphine provides pre- and postoperative analgesia for these patients.
- Compounded gabapentin has shown benefit in severely painful cats.
- Intraoperative regional nerve blocks provide

analgesia for 6 to 8 H and decrease anesthetic depth and mean alveolar concentration of inhalants.<sup>10</sup> The addition of an opioid to bupivacaine is sufficient to provide analgesia for approximately 48 to 72 H.<sup>11,12</sup>

- Usage of an approved nonsteroidal anti-inflammatory (NSAID) in the postoperative phase of therapy compliments analgesic therapy.

## REFRACTORY CGS TREATMENT

The author defines *refractory* as no improvement 60 days post full mouth extraction. As mentioned earlier, approximately 10% of CGS surgical cases are refractory, and these pose a very difficult therapeutic challenge to the clinician. Following are the most current treatment modalities available, with a peek at one of the most promising options for refractory CGS.

## Corticosteroids

Historically, corticosteroids (eg, prednisolone) have been used for refractory cases, with limited to moderate success. Immunosuppressive dosages are recommended if this class of drug is chosen (**Table 3**). Assessment of clinical improvement is needed every 30 days.<sup>13</sup>

There are undesirable clinical and physiological effects of chronic corticosteroid usage, such as polyuria and polydipsia, thinning of haircoat, behavioral changes, and diabetes mellitus. In a recent study evaluating efficacy of prednisolone, 13 of 16 cats did not respond favorably, with deleterious clinical signs.<sup>1</sup>

**TABLE 2 Recommended Perioperative Analgesics for Partial or Full Mouth Extractions**

DRUG	DOSAGE/ADMINISTRATION	PERIOPERATIVE PERIOD
<b>Buprenorphine</b>	0.02 mg/kg sublingually Q 8–12 H	Preoperative Postoperative
<b>Gabapentin</b>	5–10 mg/kg Q 12–24 H	Preoperative Postoperative
<b>Regional nerve block: Buprenorphine + bupivacaine</b>	Buprenorphine (0.3 mg/mL): 0.05 mL Bupivacaine (0.5 mg/mL): 0.95 mL <i>Inject 0.25 mL per regional nerve block</i>	Intraoperative
<b>Robenacoxib*</b>	1–2 mg/kg PO Q 24 H	Postoperative

\*If previous corticosteroid therapy has been used, an appropriate washout period must be considered before administering an approved NSAID.

**TABLE 3 Medical Therapy Options for Refractory CGS**

DRUG	DOSAGE
Prednisolone	<ul style="list-style-type: none"> <li>• 3–4 mg/kg PO Q 24 H for 3–4 weeks</li> <li>• Taper by approximately 25% per month</li> </ul>
Microemulsified cyclosporine suspension	2.5 mg/kg PO Q 12 H
Modified cyclosporine	7.5–10 mg/kg PO Q 24 H
Feline recombinant interferon omega	<ul style="list-style-type: none"> <li>• Inject 2.5 MU in the inflamed right caudal mucosa</li> <li>• Inject 2.5 MU in the inflamed left caudal mucosa</li> <li>• Dilute the remaining 5 MU in 100 mL sterile saline and separate into 10 mL fractions</li> <li>• Keep 1 syringe in the refrigerator and freeze the remaining syringes</li> <li>• Administer 1 mL PO Q 24 H, alternating sides of the mouth daily, until all 100 ML has been administered</li> </ul>

## Cyclosporine

Cyclosporine is a potent immunosuppressive agent that inhibits T cell activation by blocking the transcription of genes coded for specific pro-inflammatory cytokines interleukin-2 (IL-2) and IL-4. If this positive feedback loop of T cell activation by IL-2 is suppressed, the inflammatory process can be minimized. The mechanism of action of cyclosporine is to minimize IL-2 expression, which subsequently minimizes T cell numbers.<sup>1</sup>

A recent study showed significant clinical improvement using cyclosporine (**Figures 8 and 9**, page 32).<sup>1</sup>

- A notable outcome of this study revealed more favorable clinical success with patients that have *not* received previous corticosteroids (69% versus 45%).<sup>1,4</sup>
- This double-blind study evaluated 16 cats administered a microemulsified cyclosporine suspension (Neoral, [novartis.com](http://novartis.com)).<sup>1</sup> The cyclosporine product was compounded at 2.5 mg/kg per 1 mL in a cod liver oil base, with tuna flavoring, and it was administered at 1 mL PO Q 12 H.

## What You Will Need

Proper equipment (**Table 4**) and knowledge of mucogingival flap presentation are essential to attain maximum clinical success.

### Equipment

A variety of burs and diamonds are needed to facilitate extraction and alveoplasty. Instruments, such as a Minnesota retractor and DeBakey tissue forceps, can help prevent tissue maceration during the procedure. Fine luxators or periostomes help fatigue the periodontal ligament without damaging the surrounding alveolar bone. Magnification and illumination are essential for this procedure, or any oral surgery.

### Knowledge

While this article does not address the step-by-step procedure to perform quadrant extractions, it is prudent to review current literature or even take one or multiple laboratories to attain clinical competency.

**TABLE 4 Equipment Necessary to Successfully Perform Tooth Extractions**

#### EQUIPMENT LIST

#15 or 15C scalpel blades
Minnesota retractor for isolation of the tongue and surrounding soft tissue
DeBakey tissue forceps
Fine, sharp luxators and/or periostomes
Variety of burs: #½, #1, and #2 round; #701L or #699 crosscut; medium grit football and conical diamonds
Periosteal elevators specific for cats or small dogs
Sharpened #2, #3, and #4 winged elevators
5-0 poliglecaprone-25 or chromic gut with a P3 needle

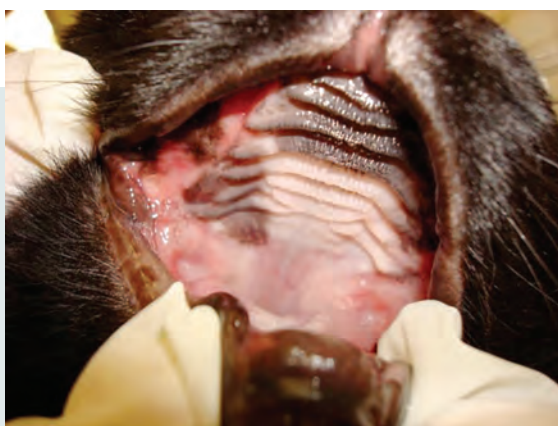More recently, a once-daily modified cyclosporine (Atopica, [us.atopica.com](http://us.atopica.com)) is now available for cats (**Table 3**). The dosage for that product is 7.5 to 10 mg/kg Q 24 H, as it needs to be given at higher dosages than microemulsified cyclosporine to achieve adequate blood levels.

Establishing trough whole blood cyclosporine levels (attained 12 H after the last dosage given) > 300 ng/mL demonstrated the most significant clinical improvement (72%).<sup>1</sup> Trough whole blood cyclosporine levels should be tested monthly if there is no clinical improvement. The goal of > 300 ng/mL should be attained and, if values are lower, treatment dosage is increased accordingly.

Transient vomiting and diarrhea are the most common side effect of cyclosporine. Informed consent of the usage of cyclosporine is important as well as future costs associated with this medication. Outdoor cats or cats eating a raw diet should be tested for *Toxoplasma gondii* prior to cyclosporine therapy.<sup>1,4</sup>

## Feline Recombinant Interferon Omega

Feline recombinant interferon omega (rFeIFN- $\omega$ ) is available in the United States only through the Food and Drug Administration (FDA) Compassionate Use Program and is imported on an individual basis. This drug is licensed to treat retroviral infections and studies have shown that interferon delivered transmucosally was as effective as prednisolone in decreasing clinical signs. It is



**FIGURE 8.** Refractory caudal mucositis after full mouth extractions. Courtesy Milinda Lommer, DVM, DAVDC

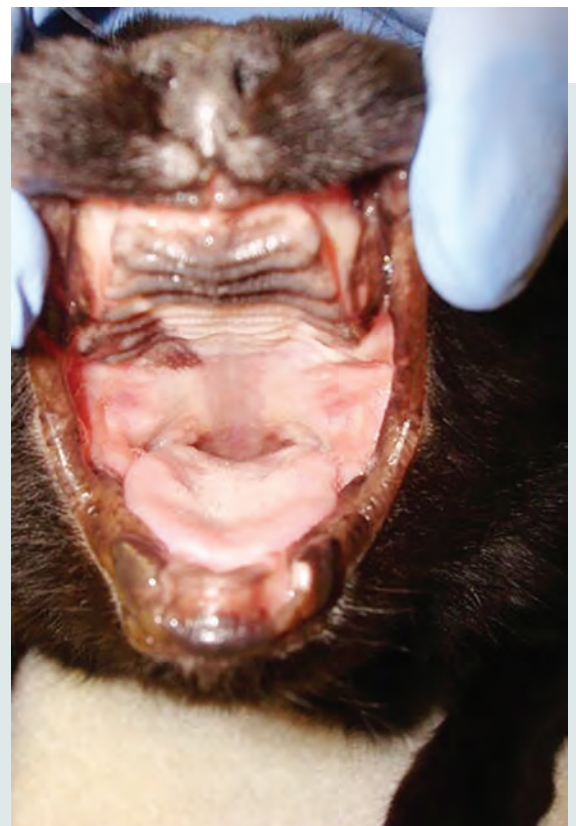packaged in a 10 million (MU) vial (**Table 3**); there are no adverse side effects to rFeIFN- $\omega$ .<sup>14</sup>

## CO<sub>2</sub> Laser Therapy

CO<sub>2</sub> laser therapy has been described as an adjunct therapy for refractory stomatitis (**Figures 10 to 12**).<sup>15</sup> The goal of therapy is to char the inflamed tissue, which results in scar tissue formation, and this scar tissue is considerably less likely to become inflamed over time. However, the veterinarian must be extremely proficient in the usage of this laser; hospitalization, placement of an esophagostomy tube, and corticosteroid therapy are frequently necessary. This therapy may be repeated in 4 to 6 weeks, if needed.<sup>15</sup>

## Adipose-Derived Mesenchymal Stem Cell (ASC) Therapy

Mesenchymal stem cells have been associated with regenerative ability, in part due to their ability



**FIGURE 9.** Resolution of caudal mucositis after cyclosporine therapy. Courtesy Milinda Lommer, DVM, DAVDC



to modulate both innate and adaptive immune responses. These cells are adherent, fibroblast-like, multipotent stem cells derived from a variety of tissues, including adipose tissue.<sup>2</sup>

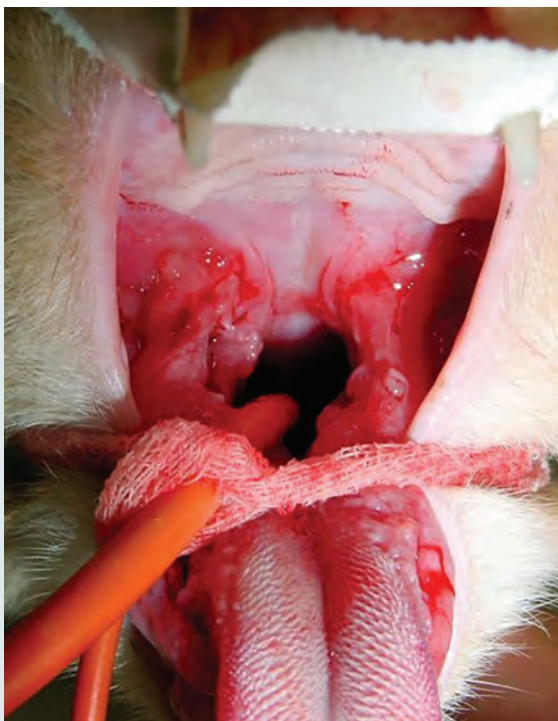
The goals of a recent study were to evaluate the effectiveness of adipose-derived mesenchymal stem cell (ASC) therapy in cats with CSG and possibly establish correlation of this therapy in human counterparts with similar pathology.<sup>2</sup>

- The study hypothesized that ASC therapy would result in systemic immune modulation, inflammatory lesion reduction, and clinical sign improvement, either by complete cure or substantial reduction in inflammatory lesions; this hypothesis was confirmed by clinical, histopathologic, and immunologic testing.
- The 7 of 9 cats that completed this study received 2 IV injections of 20 million autologous ASCs administered 1 month apart.<sup>2</sup>
- Of those 7 remaining cats, 5 responded to treatment by either complete clinical remission (3 cats) or substantial clinical improvement (2 cats).<sup>2</sup>

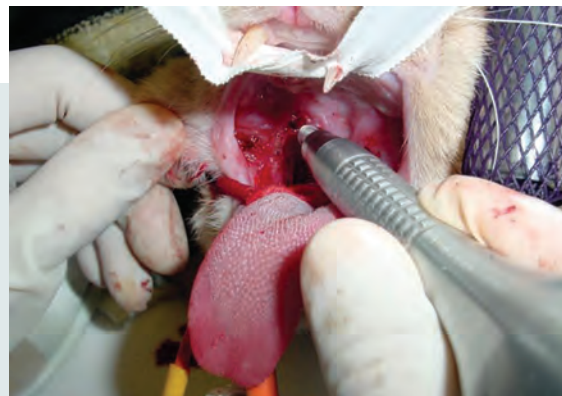- Each cat was hospitalized posttransfusion for 2 to 3 days to monitor for possible adverse reactions.

The researchers also established that cats with < 15% CD8 cytotoxic T cells (with low expression of those cells) were 100% responsive to ASC therapy, while cats with > 15% CD8 cytotoxic T cells responded poorly.<sup>2</sup> This biomarker may assist clinicians in predicting clinical response to ASC therapy.

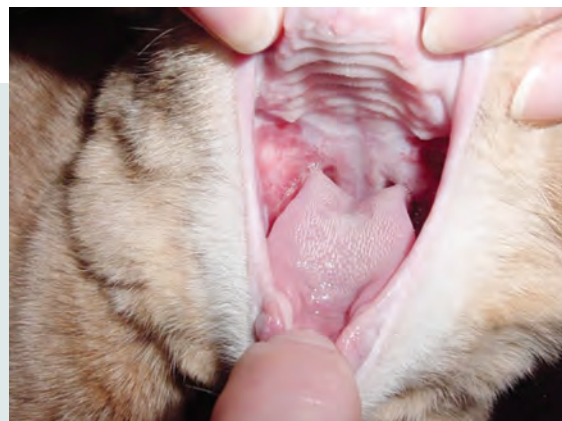Once the ability to preselect favorable clinical cases is standardized and proper culture expansion and characterization are made commercially available, this favorable treatment for CGS provides an excellent opportunity for substantial or total clinical resolution of previously nonresponsive cats.



**FIGURE 10.** Severe refractory caudal mucositis despite previous extraction of premolars and molars. Courtesy John Lewis, DVM, DAVDC, FAVD, and the University of Pennsylvania



**FIGURE 11.** CO<sub>2</sub> laser ablation for refractory caudal mucositis; the canine teeth were extracted at the same time. Courtesy John Lewis, DVM, DAVDC, FAVD, and the University of Pennsylvania



**FIGURE 12.** Healed caudal oropharynx after treatment with CO<sub>2</sub> laser. Courtesy John Lewis, DVM, DAVDC, FAVD, and the University of Pennsylvania



## Learn More

Learn more about adipose-derived mesenchymal stem cell therapy by reading **Regenerative Medicine for Soft Tissue Injury & Osteoarthritis** in the July/August 2016 issue of *Today's Veterinary Practice*, available at [tvjournal.com](http://tvjournal.com).

## IN SUMMARY

CGS is a complex syndrome for which a true cause-and-effect has yet to be established. Until that time, partial or full mouth extractions are the gold standard of therapy. Complete tooth removal—with absolutely no tooth root remnants remaining—is essential for progression to clinical improvement. Utilization of dental radiography is not an option but rather an essential diagnostic and confirmational tool to ensure complete removal of the entire tooth.

Confident knowledge of surgical flaps and quadrant extractions is highly recommended prior to undertaking this oral surgery. The veterinarian should have the appropriate armamentarium available to perform quadrant extractions in the cat, but the best tool for the clinician is patience.

Use of systemic antibiotics in lieu of partial or full mouth extractions is ill-advised, and only contributes to possible antibiotic resistance in patients. At the immediate intra- and postoperative phases of treatment, antibiotics may aid in soft tissue healing; however, chronic, long-term use of antibiotics has not been documented to be effective.

Transitioning the patient to canned food (with an appetite stimulant, if needed) prior to surgery, minimizing chronic oral pain with opioid therapy (eg, buprenorphine) and gabapentin, and removing all tooth structures provide the practitioner the best chance of clinical success.

Addressing the immediate postoperative phase is critical. Utilizing buprenorphine in the regional nerve blocks provides prolonged analgesia. Additionally, an opioid and ketamine loading dose followed by a constant rate infusion (CRI) or a fentanyl CRI immediately prior to and following anesthesia can augment the opioid administered in the regional block.

Finally, refractory CGS cases should be treated with corticosteroids, cyclosporine, feline recombinant interferon omega, or CO<sub>2</sub> laser. With ASC therapy available in the future, clinicians will have another option for treating refractory cases of CGS. **TVP**

## References

1. Lommer MJ. Efficacy of cyclosporine for chronic, refractory stomatitis in cats: a randomized, placebo-controlled, double-blinded clinical study. *J Vet Dent* 2013; 30(1):8-17.
2. Arzi B, Mills-Ko E, Verstraete FJ, et al. Therapeutic efficacy of fresh, autologous mesenchymal stem cells for severe refractory gingivostomatitis in cats. *Stem Cells Transl Med* 2016; 5(1):75-86.
3. AVDC accepted nomenclature, available at [avdc.org](http://avdc.org).
4. Lommer MJ. Oral inflammation in small animals. *Vet Clin North Am Small Anim Pract* 2013; 43(3):558-571.
5. Belgard S, Truyen U, Thibault JC, et al. Relevance of feline calicivirus, feline immunodeficiency virus, feline leukemia virus, feline herpesvirus and *Bartonella henselae* in cats with chronic gingivostomatitis. *Berl Munch Tierarztl Wochenschr* 2010; 123(9-10):369-376.
6. Dowers KL, Hawley JR, Brewer MM, et al. Association of *Bartonella* species, feline calicivirus, and feline herpesvirus 1 infection with gingivostomatitis in cats. *J Feline Med Surg* 2010; 12(4):314-321.
7. Jennings MW, Lewis JR, Soltero-Rivera MM, et al. Effect of tooth extraction on stomatitis in cats: 95 cases (2000-2013). *JAVMA* 2015; 246(6):654-660.
8. Hennet P. Feline chronic gingivostomatitis: Extraction and what else? *Veterinary Dental Forum*, 2010.
9. Hennet P. Chronic gingiva-stomatitis in cats: Long-term follow-up of 30 cases treated by dental extractions. *J Vet Dent* 1997; 14(1):15-21.

continued on page 38



## Glossary

**ASC** adipose-derived mesenchymal stem cell

**AVDC** American Veterinary Dental College

**CGS** chronic gingivostomatitis

**CRI** constant rate infusion

**FCV** feline calicivirus

**FeLV** feline leukemia virus

**FIV** feline immunodeficiency virus

**MG** mucogingival

**MU** million unit

**NSAID** nonsteroidal anti-inflammatory drug

**rFeIFN- $\omega$**  feline recombinant interferon omega

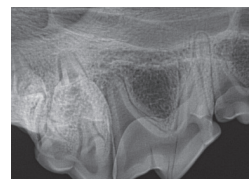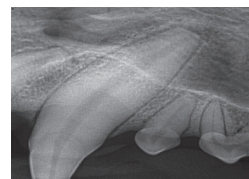
**TR** tooth resorption



# SEE MORE THAN WHAT'S ON THE SURFACE.

## DIAGNOSE BELOW THE GUM LINE WITH SCHICK 33

With more pet owners demanding high-quality veterinary dental care, it makes sense to add the Dentsply Sirona digital x-ray system with Schick 33 and HELIODENT<sup>PLUS</sup> to your practice. Together these products provide an easy solution for high-resolution intraoral radiography and the best diagnostic capabilities. Contact your Patterson Veterinary rep or learn more at [vet.schickbysirona.com](http://vet.schickbysirona.com)



Visit us at the NAVC  
PATTERSON VETERINARY BOOTH #1500



For more information:  
[VetSales@sirona.com](mailto:VetSales@sirona.com)  
or 877-SCHICKVET

THE DENTAL  
SOLUTIONS  
COMPANY™

 **Dentsply  
Sirona**



# Chronic Feline Gingivostomatitis: Proven Therapeutic Approaches & New Treatment Options

## OVERVIEW

This article, page 26, provides an overview of current and future therapeutic options for management of cats with chronic gingivostomatitis (CGS) and refractory CGS.

## LEARNING OBJECTIVES

After reading this article, participants will be able to recognize the signs of chronic CGS in cats and compare treatment options for CGS and refractory CGS.

This article is  
**RACE-approved for  
1 hour of continuing  
education credit.**  
To receive credit,  
take the approved  
test online at  
[vetmedteam.com/  
tvp.aspx](https://vetmedteam.com/tvp.aspx) (CE fee of  
\$5/article).

- 1. Which of the following is TRUE with regard to the use of cyclosporine therapy in refractory CGS?**
  - a. Minimum whole blood cyclosporine trough values of 100 ng/dL are recommended for favorable treatment outcome.
  - b. Modified cyclosporine has better oral absorption than the microemulsified version of cyclosporine.
  - c. Patients receiving prior corticosteroid therapy respond better to cyclosporine therapy than those that have not received prior corticosteroids.
  - d. The mechanism of action of cyclosporine is to minimize IL-2 expression, which subsequently minimizes T cell numbers.
- 2. CGS in cats affects approximately how much of the general cat population?**
  - a. 20% to 25%
  - b. 15% to 20%
  - c. < 10%
  - d. 30%
- 3. Which of the following is FALSE with regard to clinical and hematologic signs of CGS?**
  - a. The mucogingival line provides a landmark by which the clinician differentiates disease entities of gingivitis and stomatitis.
  - b. When inflammation occurs in the caudal oropharynx lateral to the palatoglossal folds, it is identified as faucitis.
  - c. Oral submucosal tissues are often involved in chronic gingivostomatitis cases.
  - d. Hyperglobulinemia is a common finding in these cases.
- 4. Which of the following has been implicated in active shedding during clinical cases of CGS?**
  - a. Feline leukemia virus
  - b. Feline immunodeficiency virus
  - c. *Bartonella henselae*
  - d. Feline calicivirus
- 5. Which of the following is FALSE with regard to perioperative pain management in a CGS case?**
  - a. Buprenorphine may be added to regional nerve blocks to enhance analgesia for up to 3 days.
  - b. Robenacoxib may be used with corticosteroids to provide a balanced analgesic response.
  - c. Gabapentin has shown benefit in severely painful cats.
  - d. None of the above.
- 6. Which of the following is FALSE with regard to treatment options for CGS?**
  - a. Antibiotics should not be used regularly to control the bacterial plaque formation in CGS patients.
  - b. Partial mouth extractions parallel full mouth extractions with resolution of clinical signs, provided the canines and incisors are not involved.
  - c. CO<sub>2</sub> laser therapy is a viable treatment option to char caudal mucositis lesions prior to extraction of teeth.
  - d. Pre- and postoperative dental radiography must accompany all extractions in CGS patients.

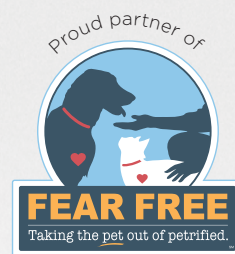continued on page 38

## NOTE

Questions online may differ from those here; answers are available once CE test is taken at [vetmedteam.com/tvp.aspx](https://vetmedteam.com/tvp.aspx). Tests are valid for 2 years from date of approval.

# Deliberately<sup>TM</sup> Different.

Accelerated Hydrogen Peroxide<sup>®</sup>  
Disinfectants for Infection Control  
& Biosecurity



## REScue<sup>®</sup> them from harsh chemicals

What makes Accelerated Hydrogen Peroxide<sup>®</sup> (AHP<sup>®</sup>) disinfectants so different? Formulating a disinfectant that kills pathogens is easy, formulating a disinfectant that kills AND is less toxic is difficult. Our Rescue<sup>™</sup> surface disinfectants were deliberately designed to be effective against a broad-spectrum of hard to kill pathogens while remaining gentle for users, animals, materials and the environment. Using Rescue<sup>™</sup> improves both animal and human health while protecting your assets by reducing the risk of exposure to harsh chemicals and deadly pathogens.

That's why we are not just **different** from what you're currently using, we are **Deliberately Different<sup>™</sup>**.

Please visit Virox Animal Health at NAVC 2017! [Booth #3609]

[ViroxAnimalHealth.com](http://ViroxAnimalHealth.com)

Contact Virox Animal Health for product distribution information.  
Sold in Canada under the brand Prevail<sup>™</sup>



Now available  
in pre-saturated  
Ready to Use Wipes!



Virox is proud to be an Emerald Member of the AAHA Strategic Alliance Program

7. Which is TRUE with regard to adipose-derived mesenchymal stem cell (ASC) therapy and a recent study using this methodology?
  - a. Commercially available adipose-derived stem cells provide an excellent alternative to other conventional treatments for refractory CGS cases.
  - b. Cats with > 15% CD8 cytotoxic T cells with low expression of those cells were 100% responsive to ASC therapy.
  - c. ASC therapy provides an excellent outpatient method for treatment of refractory CGS.
  - d. Mesenchymal stem cells have been associated with regenerative ability due in part to their ability to modulate both innate and adaptive immune responses.
8. Which of the following is FALSE with regard to CGS?
  - a. Tooth resorptions may occur simultaneously with CGS.
  - b. Food allergies can be a contributing component to CGS.
  - c. Calculus formation contributes to the exacerbation of clinical signs of CGS.
  - d. None of the above.
9. Which of the following is TRUE with regard to the use of corticosteroids for the treatment of refractory CGS cases?
  - a. When using this class of drugs, it is recommended to use the immunosuppressive dosage.
  - b. Corticosteroids enhance cyclosporine therapy, but at a low clinical dosage of 1 mg/kg PO Q 48 H.
  - c. Corticosteroids are contraindicated when using CO<sub>2</sub> laser therapy.
  - d. Thirteen out of 16 cats in a recent study responded favorably in treatment of CGS.
10. What is the percentage of refractory CGS cases after full mouth extractions?
  - a. 10%
  - b. 20%
  - c. 30%
  - d. 40%

## NOTE

Questions online may differ from those here; answers are available once CE test is taken at [vetmedteam.com/tvp.aspx](http://vetmedteam.com/tvp.aspx). Tests are valid for 2 years from date of approval.

continued from page 34

10. Beckman B. Regional nerve blocks for oral surgery in companion animals. *Compend Cont Ed Pract Vet* 2002; 24(6):439-444.
11. Modi M, Rastogi S, Kumar A. Buprenorphine with bupivacaine for intraoral nerve blocks to provide postoperative analgesia in outpatients after minor oral surgery. *J Oral Maxillofac Surg* 2009; 67(12):2571-2576.
12. Snyder C. Do locally administered opioids with local anesthesia increase anesthetic duration? *Veterinary Dental Forum*, 2015.
13. Davis EM. How I treat refractory feline chronic gingivostomatitis. *Clin Brief* 2015; Jan:19-22.
14. Hennet PR, Camy GA, McGahie DM, Albouy MV. Comparative efficacy of a recombinant feline interferon omega in refractory cases of calicivirus-positive cats with caudal stomatitis: A randomised, multi-centre, controlled, double-blind study in 39 cats. *J Feline Med Surg* 2011; 13(8):577-587.
15. Lewis JR, Tsugawa AJ, Reiter AM. Use of CO<sub>2</sub> laser as an adjunct treatment for caudal stomatitis in a cat. *J Vet Dent* 2007; 24(4):240-249.

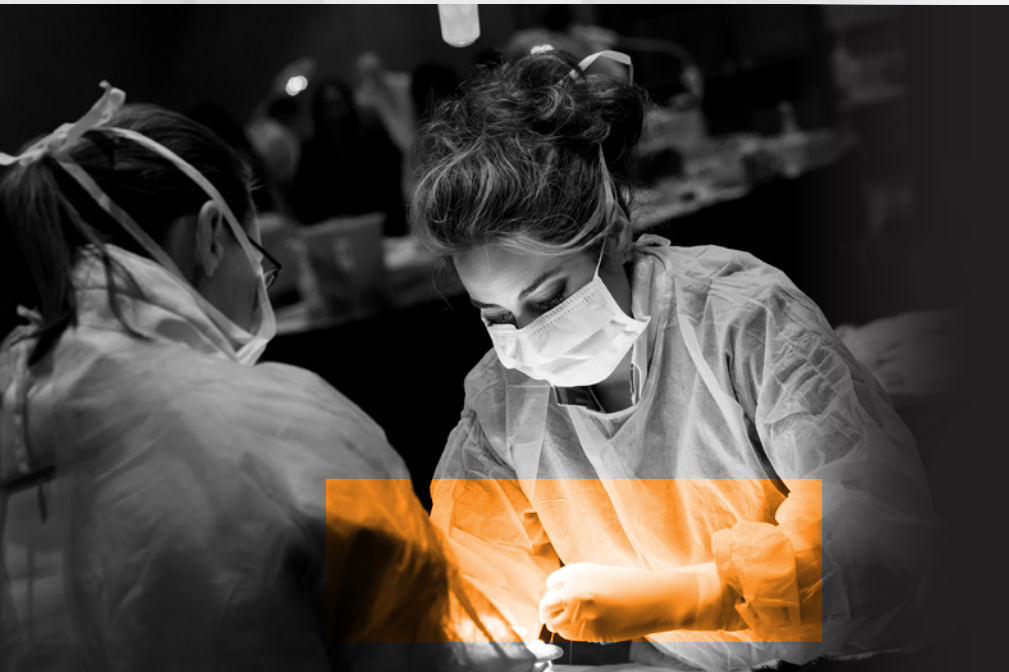

### Barden Greenfield

Barden Greenfield, DVM, FAVDC, FAVD, practices in Memphis (Memphis Veterinary Specialists) and Little Rock (Arkansas Veterinary Specialists). He is also the founder of the Mississippi Valley Veterinary Dental Educational Center (MVDDEC) in Memphis, providing dental CE to veterinarians and technicians in the central U.S. Dr. Greenfield is the president of the AVDC and has been serving on the AVDC board for the past 4 years. In addition to his clinical practice, Dr. Greenfield enjoys lecturing at the local, state, national, and international levels. He has authored multiple articles for the *Journal of Veterinary Dentistry*. Dr. Greenfield received his DVM from Mississippi State University. He may be reached at [drg@yourpetdentist.com](mailto:drg@yourpetdentist.com).



# NAVC INSTITUTE 2017



Master  
today's most  
cutting-edge  
techniques  
through total  
immersion  
skills training.

**REGISTER NOW • MAY 21-26, 2017 • ORLANDO, FLORIDA**




## 2017 Courses:

- ABVP Examination Preparation

Sponsored by:  **VetFolio**  
All you need. All in one place.

- Applied Clinical Behavioral Medicine
- Canine Sports Medicine & Rehabilitation

Sponsored by:  **ARATANA**  
THE REPTILES

- Cardiology Crossfit
- Dentistry: Sink Your Teeth Into It! Sponsored by:  **MERIAL**


- Practical Approaches to Small Animal Ophthalmology

Sponsored by:  **AKORN** ANIMAL HEALTH

- Practical Techniques in Soft Tissue & Orthopedic Surgery

Sponsored by:  **TODAY'S VETERINARY PRACTICE**

- Small Animal Ultrasound (Group 1 & Group 2)

Sponsored by:  **SOUND** ULTRASOUND



REGISTER TODAY AT [NAVCOM/INSTITUTE](http://NAVCOM/INSTITUTE)